



EXPERT REPORT

AESCULAP[®] Caiman[®]

EXPERIENCES WITH HEMOSTATIC TISSUE DISSECTION
IN LAPAROSCOPIC MYOMA ENUCLEATION

Dr. med. Alexander Keck

EXPERIENCES WITH HEMOSTATIC TISSUE DISSECTION IN LAPAROSCOPIC MYOMA ENUCLEATION

1. FOREWORD

Since 2008, I have been working full-time at the Osnabrück Hospital's Clinic for Gynecology and Obstetrics, Level I Perinatal Center, under the direction of Priv. Doz. Dr. Dr. med. Yves Garnier. The gynecological clinic consists of the Department of Obstetrics and Pre-Natal Medicine and the Department of Gynecology, along with the Osnabrück Gynecological Cancer Center (GKO), which is certified in accordance with DKG guidelines. It has a total of 64 beds and provides inpatient care to a total of 3,000 patients annually. The attached neonatal intensive care unit has 12 ventilator beds for premature infants. The Osnabrück Hospital's Birthing Center with Level I Perinatal Center assists with more than 1,300 births every year.

More than 600 laparoscopic surgeries are performed annually. In addition to the conventional spectrum of operative services, we offer laparoscopy-based oncological procedures (laparoscopic Wertheim's hysterectomies, lymphadenectomies) and laparoscopy-based urogynecological procedures (pectopexy). The different variants of laparoscopic hysterectomy represent our core business, accounting for more than 150 procedures annually.

I have ten years of professional experience, and was trained in laparoscopic techniques from the very beginning, such that I have held the German Society of Gynecology and Obstetrics - Gynecological Endoscopy Consortium's (DGGG-AGE) Level II certification in minimally invasive surgery since 2011. Hysteroscopic and laparoscopic uterine fibroid treatments are among my preferred procedures; thus far, I have performed around 350 laparoscopic hysterectomies, and around 150 of the laparoscopic myoma enucleations described here.

2. MYOMA ANATOMY

Myoma are benign muscular tumors, and are quite common in women of almost any age. Most of these women suffer no symptoms as a result of the myomas, but in some women they cause a variety of symptoms, some of which can be very troublesome. These may range from bleeding disorders to different types of abdominal pain to difficulty conceiving.

Besides surgical removal of the uterus (hysterectomy), which is offered to women whose family planning is complete, myoma-related symptoms can also be treated using medication. The goal is to suppress estrogen production for the duration of treatment in order to alleviate existing symptoms.

Organ-conserving operations provide a solution for women with a desire to have children in the future. In these procedures, the surgeon attempts to peel only the fibroids out of the surrounding musculature, while keeping the uterus as such intact. In many cases (though not all), this can be done laparoscopically. If a myoma has grown into the uterine cavity, we will attempt to remove it surgically in a hysteroscopy. Preserving the uterus is a primary goal in procedures of this type as well.

3. CASE STUDY

I will describe the case of a 41-year-old patient who began experiencing recurrent hyper- and metrorrhagia along with dysmenorrhea following a spontaneous delivery six years earlier. A sonogram has revealed a large rear wall fibroid that appears easily accessible for myoma enucleation, such that the patient expresses a desire to conserve the organ. The patient is given comprehensive information about the procedure, its indication and its associated risks, and gives her written consent. Before the operation, anesthesia delivery capability is assessed in consultation with the

anesthesiologist, and the estimated length and scope of the operation are determined. The operation is performed under intubation anesthesia. We perform our standard safety procedure, "Team Time Out". The patient is initially positioned horizontally with shoulder rests and leg stirrups, and with both arms padded and fixed with a cloth, so that the team can come closer to the patient (i.e., less hunched over).

After disinfection, the straight stab incision is made (11 scalpel) into the lower umbilical line of reflection. Veress needle inserted. In my experience, patients experience less post-operative pain if the relaxed abdominal wall is not grasped and lifted forcefully during this stage and the subsequent introduction of the optical trocar, as is commonly done. As such, I insert the Veress needle through the fascia and peritoneum at a 45° angle without any manipulation.

Following aspiration sampling using the Semm method and establishing capnoperitoneum using 3.0 l CO₂ (15 mmHg pressure), I insert the trocar for 30° optics (also without manipulating the abdominal wall) by using its tip to find the puncture site in the fascia, then use the other hand to create a kind of hypomochlion, and then forcefully penetrate the peritoneal cavity there—also at a 45° angle.

The patient's head is then lowered by 15°, or until the intestinal loops passively shift from the pelvis minor into the central abdomen, whichever comes first. With this procedure, after doing the usual inspection of the abdominal cavity, I always create two stab incisions for the 5 mm trocars on either side of the transition from the lateral to the middle third of an imaginary line between the Spina iliaca anterior superior and the navel, and centrally along the upper edge of the pubic hair, using diaphanoscopy.

In this particular operation, no pathological findings are observed in the organs of the central and upper abdomen, apart from adhesions between the Omentum majus and the front abdominal wall, which must first be removed.

The Aesculap® Caiman® proved itself for the first time here: gripping the adhesions close to the abdominal wall is effortless, and thanks to the instrument's low thermal spread (<1 mm), they can easily be coagulated and removed without damaging organs. Now I have a clear line of sight into the pelvis minor: there is a large Uterus myomatosus with an isolated, intramural rear wall myoma 8 cm in size. Both tubes are soft along their entire length, with no fluctuations in diameter and mobile, free fimbrian funnels. The right ovary is normal; the left, as was suspected following a pre-

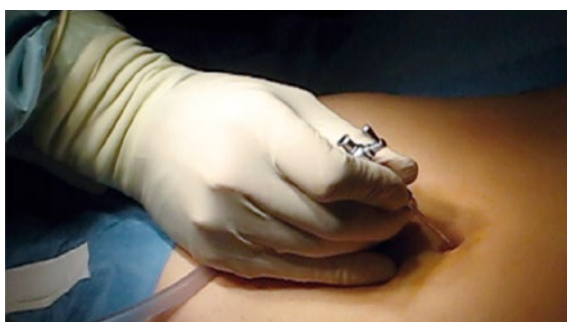

Fig. 1 Incision with Veress needle

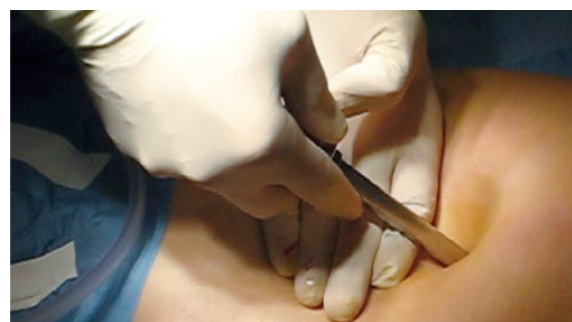

Fig. 2 Inserting the optical trocar

EXPERIENCES WITH HEMOSTATIC TISSUE DISSECTION IN LAPAROSCOPIC MYOMA ENUCLEATION

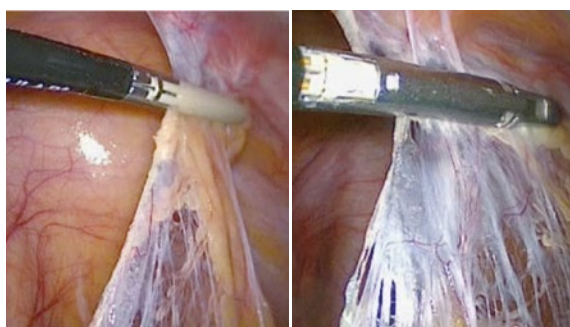


Fig. 3 /4 Using the Caiman® on adhesions between the Omentum majus and the front abdominal wall

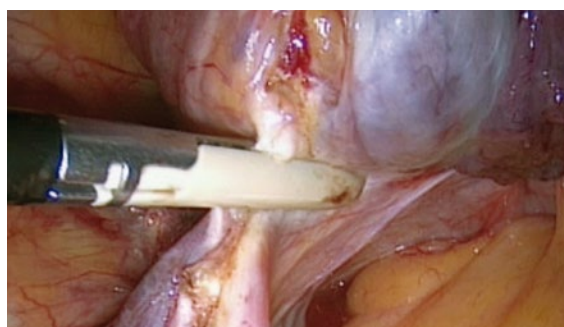


Fig. 5 Dissecting the Lig. suspensorium ovarii sinister

operative sonogram, is distended by an endometrioma. As the cyst has completely surrounded the ovary, I decide to perform a unilateral adnexectomy, for which the patient has given consent.

After exposing the intraperitoneal ureter curve on the left side, I dissect the Lig. suspensorium ovarii sinister and use the Caiman® 5 for targeted coagulation. Remarkably, the tissue is actually only severed after sufficient coagulation has been achieved. After further dissection of the left-hand adnexa, I deposit the dissected tissue into the Douglas cavity for later retrieval and turn my attention to the main purpose of the procedure.

The rear wall myoma is easy to make out; in cases where myomas are difficult to differentiate, slow intravenous dosage of 0.2 mg methylergometrine has proven useful, as the myoma protrudes forth from the level of the contracting myometrium. Generally speaking, I begin myoma enucleation by inserting a 20-gauge needle (38 mm long) into the abdominal wall; I use this needle as a guide for a second, 25-gauge spinal needle, which is an excellent instrument for aquadissection of the myoma capsule. I use a solution of 1 ml epinephrine 1 mg/ml diluted in 100 ml saline solution for this.

After incision into the myoma, slowly withdrawing while simultaneously injecting at the place of least resistance makes it possible to place 10-20 ml directly at the myoma capsule. For one thing, this loosens the boundary layer between myoma and myometrium; for another, the epinephrine has a certain hemostatic effect due to vascular constriction. After that, I use a monopolar hook to lay a line of coagulation on the uterus over the myoma. I make sure to make the incision slightly "too small" for the diameter of the myoma. This provides better visibility, as less blood can seep from the myoma bed into the abdominal cavity, and the distance to be sutured is shorter. The myoma usually bulges partway into the incision after opening. Now, I expand the central working channel to 10 mm and secure the myoma with the myoma drill I have inserted. Through repetitive torsion of the myoma, alternating with targeted dissection of the tissue bridges with the Caiman® 5 as they are exposed, the myoma can gradually be loosened from its bed. Thus, without having to change instruments, we can perform successive bipolar vessel sealing with minimal thermal spread (<1 mm) and separation of fibers and vessels. Eliminating the need to switch instruments repeatedly during this phase of the procedure—which can be very time-consuming due to the circumference

of the myoma—adds up to a great deal of saved time. After dissecting the last tissue bridges on the rear base of the myoma, which can generally still just barely be displayed with the 30° optics in use, the myoma is deposited into the upper abdomen. Using an angled instrument may be helpful for this last step of the procedure. The myoma enucleation opens up the Cavum uteri. I use two needle holders, inserted centrally and to the left, to place several intracorporeally tied single interrupted sutures using strength 3/0 absorbable suture material (HR26): first in order to adapt the endometrium, and then to suture the myometrium and thus reconstruct the uterus. I do this by running the needle through the left-hand working channel with the needle holder. With slim patients, another alternative is to press the needle through the abdominal wall near the navel with an open needle holder.

A single slow intravenous dose of 0.2 mg methylergometrine can be helpful during the suture phase as well, in order to reduce bleeding and thus improve visibility. Many different variations can be observed in uterine suture. Some of my colleagues use a continuous stitch; others use a barb stitch, and American colleagues often favor the so-called baseball stitch. Ultimately, the uterus has major potential for reconfiguration, as becomes evident during a subsequent Caesarean section or laparoscopy: oftentimes, the surface of the uterus bears little evidence of having been previously sutured. After careful hemostasis and extensive flushing, we morcellate using the same 12 mm morcellator we have been using with absolute satisfaction for years. We generally expand the central incision to 12 mm for this. After gradually retrieving the morcellated myoma and the adnexa resected at the start of the procedure, the structural integrity of the abdominal wall is restored using fascial suture. Another extensive round of flushing is performed, after which the flushing solution is suctioned out. Depending on the size of

the myoma enucleation, I may do gravity drainage using the Robinson method; I try to avoid this whenever possible, however, for reasons of asepsis.

4. CONCLUSION

The Caiman® 5 is a powerful instrument, and this procedure allows it to shine once more. This particular procedure is most often performed using simple, reusable bipolar coagulation systems, which is due to the more diffuse bleeding surfaces and less for reasons of targeted coagulation. However, the repetitive sealing-dissection sequence involved here means that using the Caiman® 5 can provide significant time advantages. Thus, the Caiman® 5 stands in direct competition with disposable instruments that rely upon either ultrasonic technology, monopolar coagulation, or a combination of the two, and can also cut at the same time. As is so often the case, technical reliability, manageability, and the surgeon's personal preferences are all factors in determining the instrument of choice. Based on these criteria, I favor the Caiman® 5 over other disposable systems for use in laparoscopic myoma enucleation.

EXPERIENCES WITH HEMOSTATIC TISSUE DISSECTION IN LAPAROSCOPIC MYOMA ENUCLEATION



CONTACT / AUTHOR

Dr. med. Alexander Keck

Senior Physician

Clinic of Gynecology and Obstetrics


Osnabrück Hospital

Academic Teaching Hospital of the Westphalian Wilhelm University of Münster

Am Finkenhügel 1

49076 Osnabrück

Germany



AESCULAP[®] – a B. Braun brand

Aesculap AG | Am Aesculap-Platz | 78532 Tuttlingen | Germany
Phone +49 7461 95-0 | Fax +49 7461 95-2600 | www.aesculap.com

The main product trademark "Aesculap" and the product trademark "Caiman" are registered trademarks of Aesculap AG.

Subject to technical changes. All rights reserved. This brochure may only be used for the exclusive purpose of obtaining information about our products. Reproduction in any form partial or otherwise is not permitted.